

SHARP DEBRIDEMENT MADE EASY

Anfal Nooh, M. Yusof Abdullah, Rohani Ahmad, Farah Nabila, Maliny Dawamany, Department of Pediatric Surgery, Hospital Tunku Azizah, Malaysia & MDM Wound Ventures



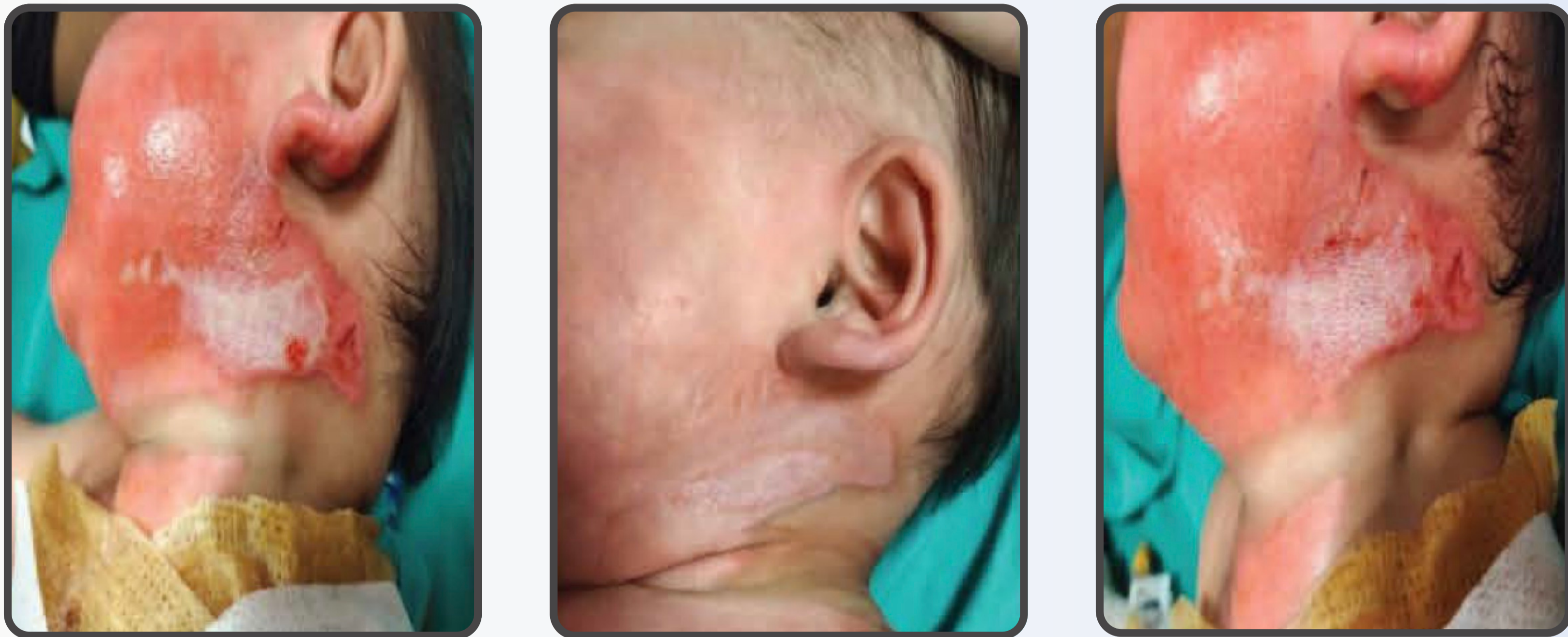
Introduction

Debridement, the removal of nonviable tissue, forms the foundation of wound care practice. Various forms have been described: surgical, sharp, autolytic, enzymatic, mechanical, and bio-surgical. Among them, surgical and sharp debridement's are the quickest way to remove the nonviable, unhealthy material from the wound beds. Sharp debridement, using a scalpel or curette, is performed to remove lesser amounts of devitalized, unhealthy tissue. This prospective study evaluated a debridement instrument, EZDebride. Cutting flutes on the head of the tool permit uniform removal of dead tissue while lessening the risk of deeper injury.

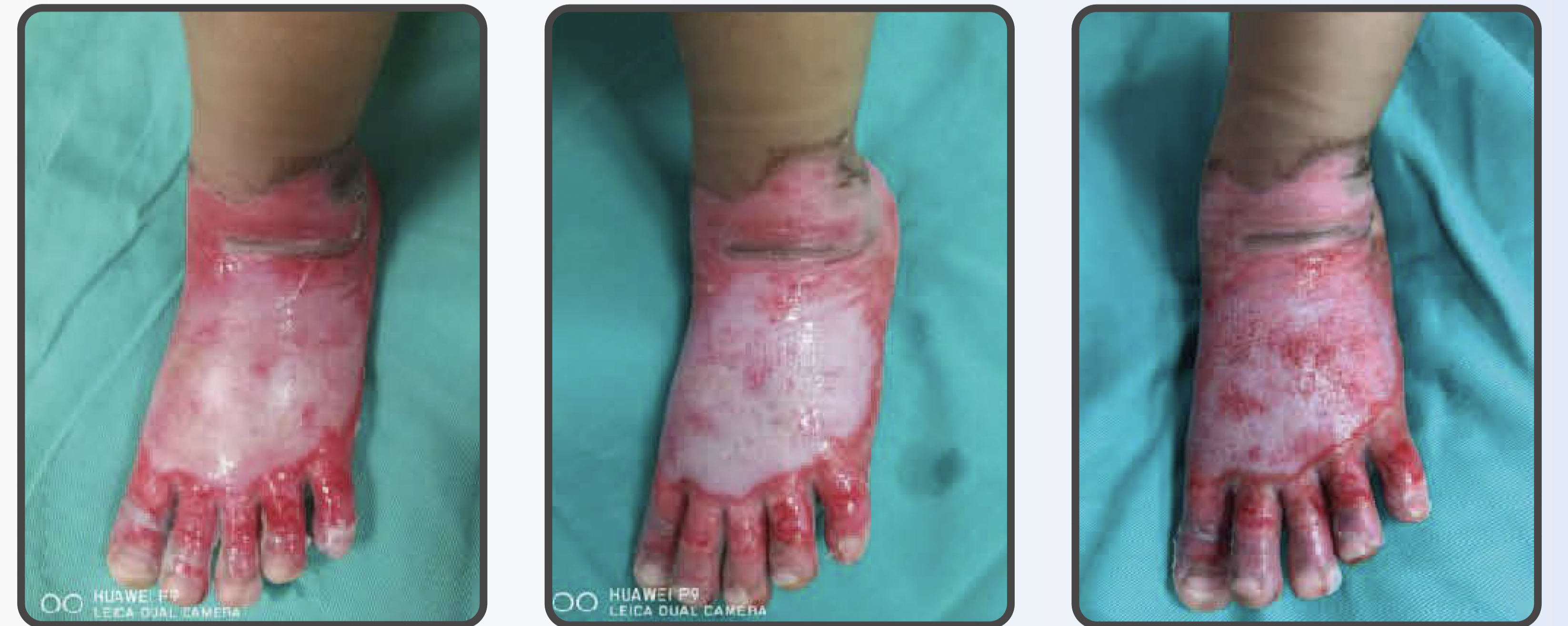Methodology

This study was conducted in the Pediatric Burn Unit, Hospital Tunku Azizah, Kuala Lumpur. A total of 5 pediatric patients were chosen, ages from 1 year to 10 years old with a superficial to full thickness burn. The EZDebride Instrument was used to debride nonviable tissue and advance wound dressings were applied. The patients were given analgesic medications appropriately before the procedure and following the dressing application in the ward.

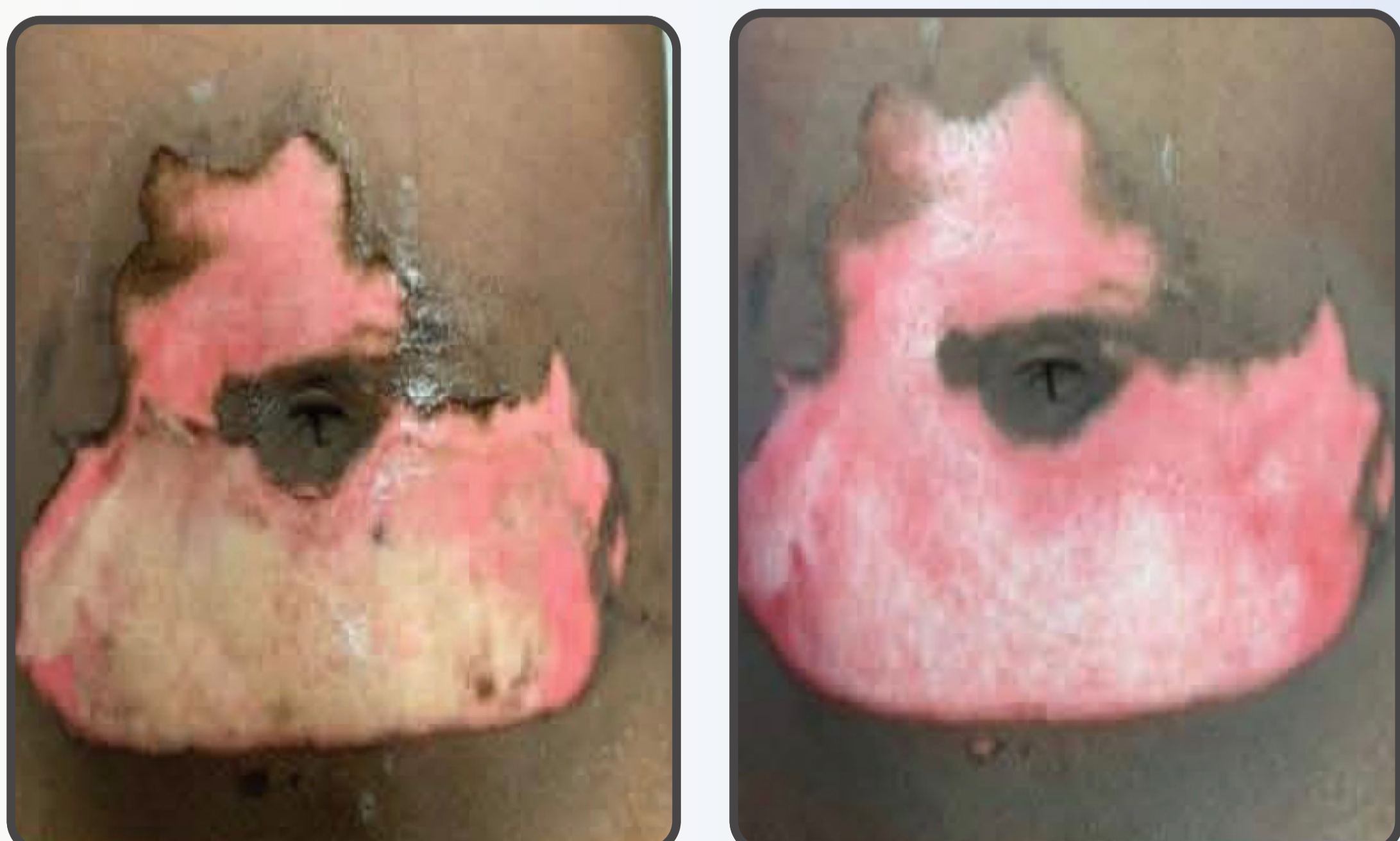A 1 year 2 month old boy with a 10% superficial to partial thickness burn over his face, neck, and anterior trunk by thermal hot water. Debridement was done using EZDebride, and modern dressing was then applied. The wound healed in 3 days, at a shorter duration time compared to normal practice.



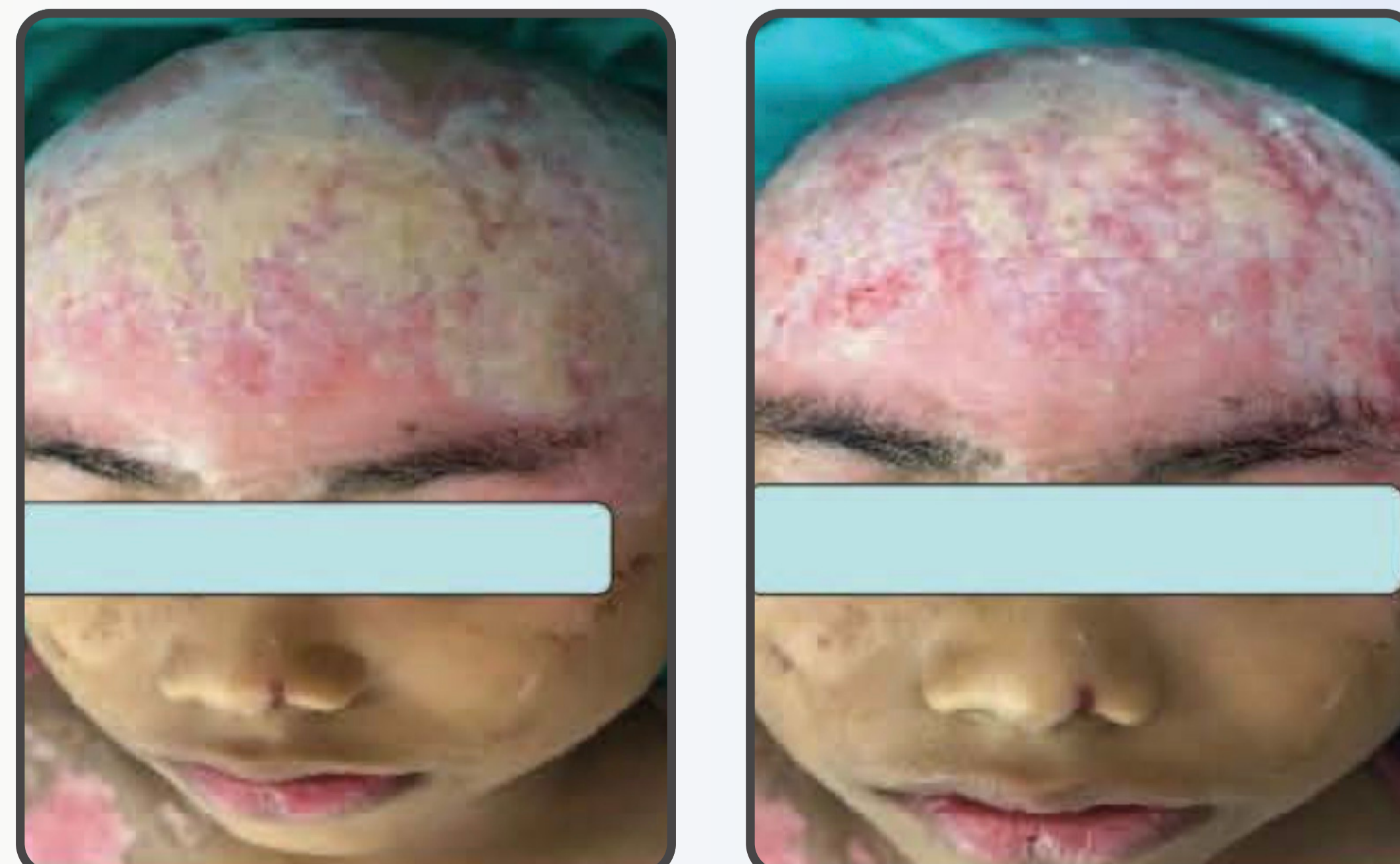A 1 year 6 month old boy with a 3% partial thickness burn over bilateral his foot by hot cooking oil. Debridement was done using EZDebride, and modern dressing was applied. Shorter duration of time for wound healing compared to normal practice.



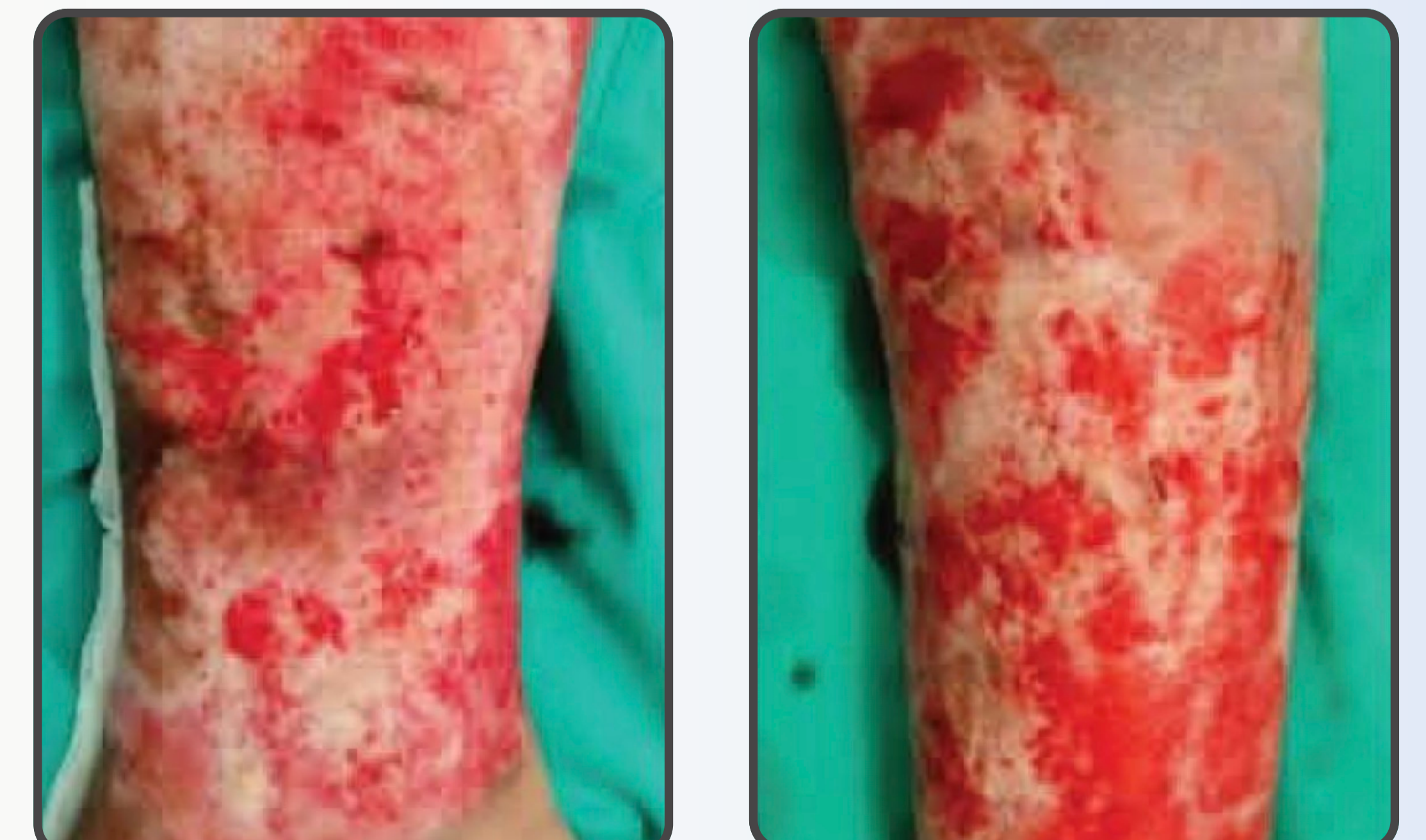A 9 year 3 month old boy with a 3% partial to full thickness burn over anterior abdomen region by flame injury.



An 8 year 10 month old boy with a 15% partial thickness burn over his scalp, facial region, bilateral shoulders, back, right lower abdominal region and bilateral thighs by hot oil.



A 9 year 3 month old boy with a 10% partial to full thickness burn over his lower limb by flame injury.



Conclusion

Debridement is an essential procedure in the treatment plan. It removes slough and nonviable tissue and disrupts bacterial biofilms. A large clinical trial evaluating more than 300,000 patients demonstrated that weekly debridement promoted wound healing better than less frequent or no debridement. In this study, we were able to observe the same efficiency with the EZDebride Wound Instrument. With the EZDebride Wound Instrument, we have found that we can complete sharp debridement in the ward and reduce the need for surgery under general anesthesia.

