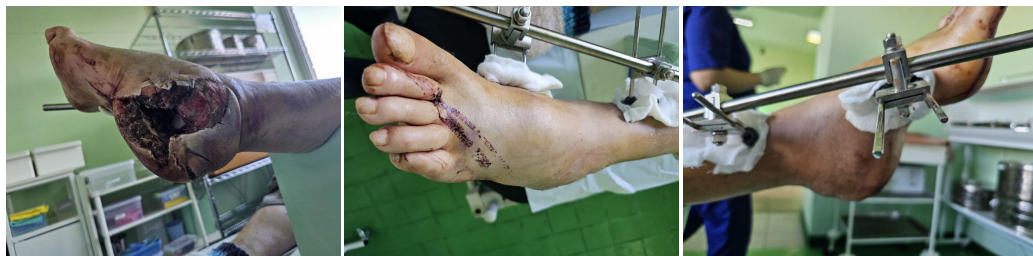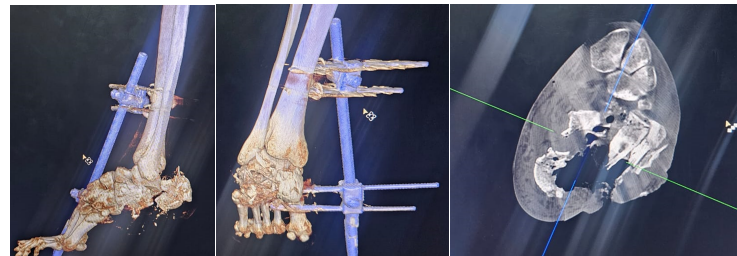


The Use of the EZDebride Wound Instrument for Surgical and Wound Care Staging in a Combat Mine Explosive Foot Injury

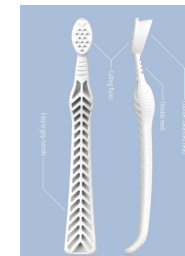
Abstract: This is a presentation of a Ukraine Soldier who underwent limb salvage procedures including surgical debridement and external fixation secondary to a severe ballistic injury to his left lower extremity. The patient presented with a large wound of the lateral rearfoot, devitalized tissue, and comminuted fractures. **Methods:** The EZDebride Wound Instrument was utilized throughout the perioperative, post-operative, and multi-modal care treatment phases which included the use of negative pressure and a split thickness skin graft to determine its efficacy in a complex trauma and wound care presentation. **Conclusion:** The author found the EZDebride Wound Instrument to be extremely effective in the debridement of the devitalized tissue and wound bed preparation for advanced wound technologies including negative pressure and a split thickness skin graft application.



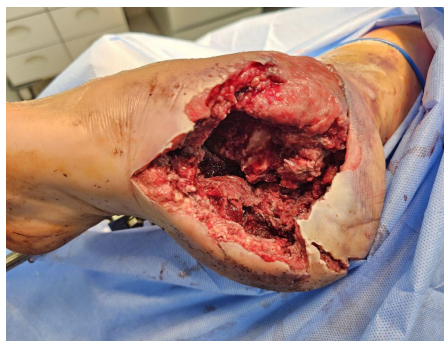Status Post Day 4: dressing removal, EZDebride Sharp Debridement: Negative Pressure



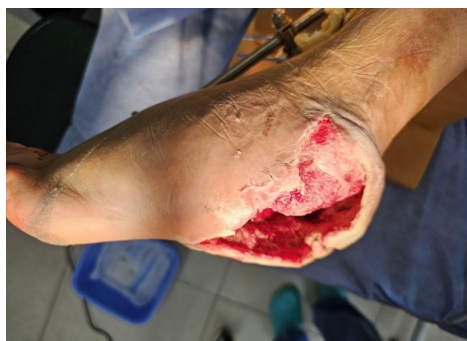CT Scan: fragmented calcaneus, distal tibial fx, cuboid and metatarsal fxs, multiple soft tissue defects



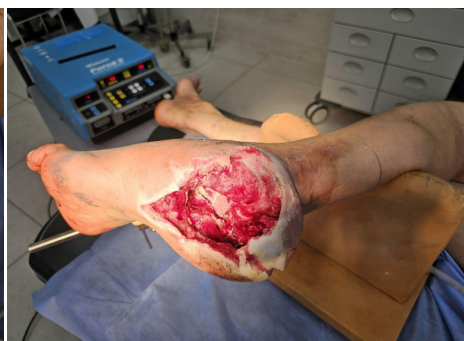Oleksandr Dunayev, MD
Ukraine Burn Center



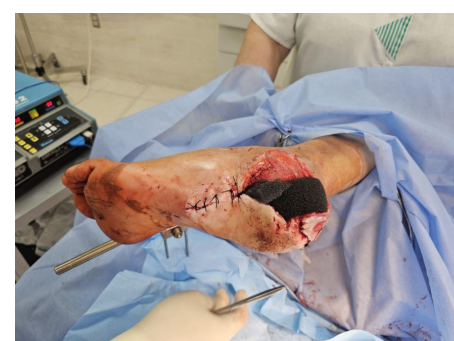Negative Pressure Removed
Status Post Day 7



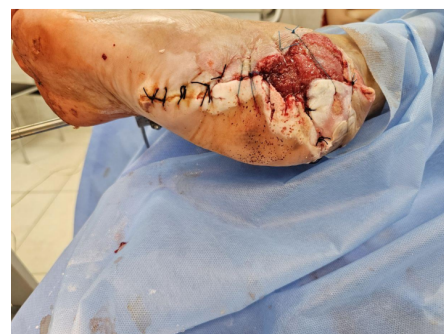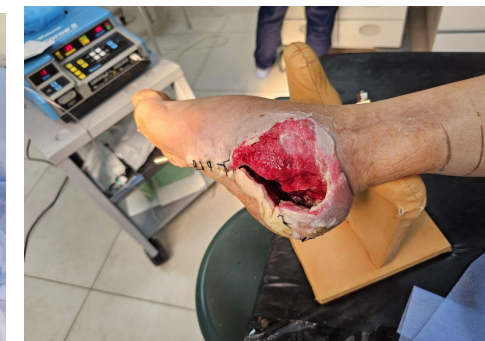Wound Bed Preparation S/P Day 7: EZDebride Sharp Debridement



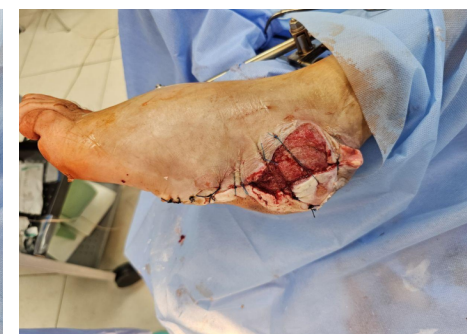S/P Day 14



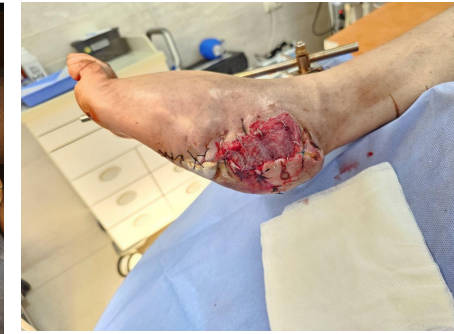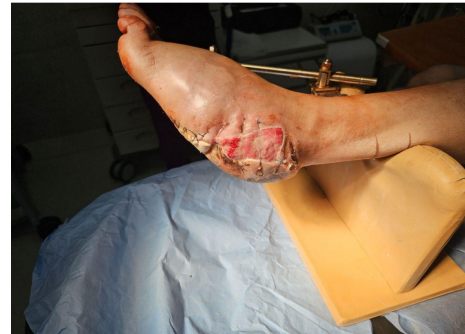S/P Day 14: EZDebride



S/P Day 14: EZDebride Sharp Debridement: Retention Sutures



S/P Day 21: EZDebride Wound Bed Preparation: Graft Application



S/P Day 24: Dressing Removal

